

Midfoot Arthritis

Amar Patel, MD
 Smita Rao, PT, PhD
 Deborah Nawoczenski, PT, PhD
 Adolf S. Flemister, MD
 Benedict DiGiovanni, MD
 Judith Baumhauer, MD, MPH

Abstract

Midfoot arthritis is a common cause of significant pain and disability. Although the medial tarsometatarsal (TMT) joints provide $<7^\circ$ of sagittal plane motion, the more mobile lateral fourth and fifth TMT joints provide balance and accommodation on uneven ground. These small constrained TMT joints also provide stability and translate the forward propulsion motion of the hindfoot and ankle joint to the forefoot metatarsophalangeal joints from heel rise to toe-off. Posttraumatic degeneration is the primary cause of midfoot arthritis, although primary degeneration and inflammatory conditions can also affect this area. The end result is a painful midfoot that can no longer effectively transmit load from the hindfoot to the forefoot. Shoe modifications and orthotic inserts have been the mainstay of nonsurgical management. Successful management of midfoot arthritis with orthoses is predicated on achieving adequate joint stabilization while still allowing function. Surgical intervention typically involves arthrodesis of the medial midfoot. The best treatment of the more mobile lateral column is a subject of debate.

Arthritis of the midfoot is a common cause of significant pain and disability. Although the etiology of midfoot arthritis includes primary and inflammatory processes, post-traumatic degeneration seems to be the most common cause. Injuries to the tarsometatarsal (TMT) joint complex represent $<1\%$ of all fractures¹ and affect 1 in 55,000 persons.² Foot and ankle injuries have increased in number with the advent of airbags.² This is because of the shift in energy during crashes and the resulting trauma to the relatively unprotected foot.³ In a 2007 retrospective study of motor vehicle front-end collisions involving airbag deployment, 38.4% of injuries were to the foot and ankle, second only to injuries at the hip, thigh, and knee (49.5%). The exact incidence of TMT injuries was not identified.

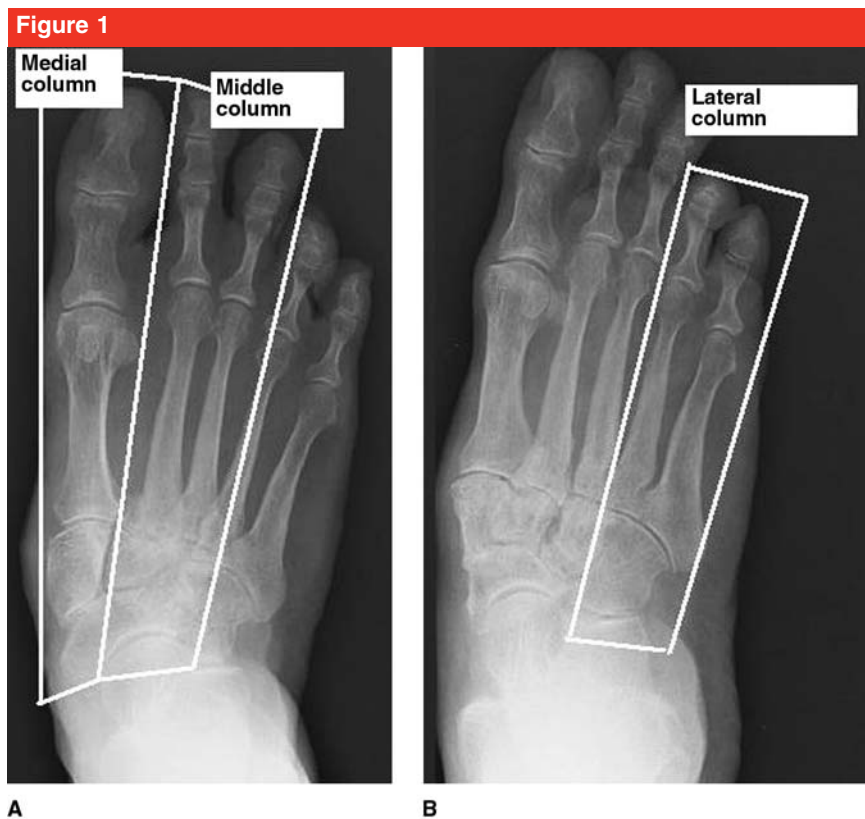
When adjusting for demographic factors, occupant height was a significant variable in determining the effectiveness of the airbag in preventing injury. Occupants shorter than 4 ft 6 in had an increased incidence of injury.³ Despite this seemingly low incidence of motor vehicle foot trauma, these injuries are particularly concerning because as many as 20% are missed or misdiagnosed.⁴ Regardless of mechanism of injury, midfoot arthritis has been reported to be the common result of significant TMT joint injury.¹ Retrospective studies have identified tarsal instability and late midfoot arthritis as major factors that contribute to poor outcomes.⁵

Shoe modifications and orthotic inserts have been the mainstay of nonsurgical management for midfoot arthritis. Successful management with

From the Department of Orthopaedics, University of Rochester School of Medicine and Dentistry, Rochester, NY (Dr. Patel, Dr. Flemister, Dr. DiGiovanni, and Dr. Baumhauer), the Department of Physical Therapy, New York University, New York, NY (Dr. Rao), and the Department of Physical Therapy, Ithaca College, Ithaca, NY (Dr. Nawoczenski).

J Am Acad Orthop Surg 2010;18:1-10

Copyright 2010 by the American Academy of Orthopaedic Surgeons.



AP (A) and oblique (B) weight-bearing radiographs of the right foot in a patient with primarily middle column midfoot arthritis. The medial, middle, and lateral columns are marked.

orthoses is predicated on achieving adequate joint stabilization while still allowing function. The ideal insert is inexpensive, allows easy fabrication, and is cosmetically acceptable to the patient. Surgical intervention can be challenging for many reasons—the complex anatomy of the region, difficulty in identifying the specific joints to be treated, and the potential for unsuccessful fusion of these multiple artic-

ulations. Although the Chopart joints (ie, talonavicular, calcaneocuboid) can occasionally be included in the definition of the midfoot, its 6° of freedom and coupled motion with the hindfoot make it more appropriate to include it with the hindfoot. For this review, we include the TMT and naviculocuneiform articulations in the definition of the midfoot.

Midfoot Anatomy and Biomechanics

The midfoot has been divided into three longitudinal anatomic columns: medial, middle, and lateral⁶ (Figure 1). The medial column is composed of the medial cuneiform and the first metatarsal. The middle column is made up of the second and third metatarsals and the intermediate and lateral cuneiforms, respectively. The lateral column is composed of the cuboid and the fourth and fifth metatarsals. The navicular bridges the medial and middle columns. The articulation between the cuboid and navicular can vary in configuration, from true synovial joint to fibrous synchondrosis.⁷

Jacques Lisfranc de St. Martin, a field surgeon in Napoleon's army who served on the Russian front, is mistakenly identified as being the first to describe this area of the foot.⁸ In fact, Lisfranc de St. Martin described a method of forefoot amputation without osteotomy across the TMT joints, for the management of gangrene. This area of the foot then became known as the Lisfranc joint, and the associated ligament was named the Lisfranc ligament. The Lisfranc complex encompasses the five metatarsal bases and their respective cuboid or cuneiform articulations. The stability of these articulations is provided by the stout ligamentous attachments and by the bony configuration of the joints themselves. The ligamentous anatomy can be divided into plantar, in-

Dr. Flemister or an immediate family member serves as an unpaid consultant to BioMimetic Therapeutics and has received research or institutional support from Aircast (DJ Orthopaedics). Dr. Baumhauer or an immediate family member serves as a board member, owner, officer, or committee member of American Board of Orthopaedic Surgery, American Orthopaedic Foot and Ankle Society, American Board of Medical Specialties, and Eastern Orthopaedic Association; serves as a paid consultant to or is an employee of Zimmer, Carticept, DJ Orthopaedics, and Orthocon; serves as an unpaid consultant to BioMimetic Therapeutics and Aircast (DJ Orthopaedics); and has received research or institutional support from the *Journal of Bone and Joint Surgery - American Resident Journal Club*, Aircast (DJ Orthopaedics), BioMimetic Therapeutics, and Carticept. None of the following authors or any immediate family member has received anything of value from or owns stock in a commercial company or institution related directly or indirectly to the subject of this article: Dr. Patel, Dr. Rao, Dr. Nawoczenski, and Dr. DiGiovanni.

terosseous, and dorsal components.⁹ The interosseous and plantar intermetatarsal ligaments are the strongest stabilizers of this construct, and the dorsal ligaments are the weakest.⁸ In the coronal plane, the bones of the Lisfranc joints have a Roman arch configuration, with the apex at the second metatarsal. The base of this particular metatarsal is recessed in relation to the surrounding cuneiforms, which adds to its overall stability. Furthermore, there is no ligament at the 1-2 intermetatarsal base; instead, there is a second metatarsal base–medial cuneiform oblique ligament (ie, Lisfranc ligament). This biomechanical construct places the midfoot at risk of injury from torsion of the forefoot and axial load.

The midfoot complex, in conjunction with the Chopart joint, has a dynamic mechanical role that allows the center of the load to be effectively transferred through the midfoot or TMT joints to the forefoot during gait. The Chopart joint is rigid at toe-off, but during heel strike it becomes a flexible structure that increases the lever arm of the Achilles complex. The forward propulsion force is transferred through the TMT joints.¹⁰

The motion at each midfoot joint is variable.¹⁰ The lateral articulations between the cuboid and the fourth and fifth metatarsals are significantly more mobile than in the central or medial columns. The lateral column joints have arcs of motion of approximately 20° in flexion-extension and rotation. The middle cuneiform–second metatarsal articulation has the least amount of motion in the midfoot (<4° in the sagittal plane), likely as a result of its anatomic constraints.

Pathologic conditions of the midfoot (eg, ligamentous disruption after trauma, inflammatory arthropathy with synovitis and joint destruction) often lead to pain and, potentially,

instability. Loss of midfoot stability may manifest as abnormal foot posture and collapse of the longitudinal arch, causing increased tensile loading on the plantar ligaments, resulting in foot pain.¹¹ Collapse of the longitudinal arch also compromises the ability of the foot to function as a rigid lever, thereby decreasing the mechanical efficiency of the foot. The presentation of midfoot arthritis is variable, and midfoot collapse need not be present for symptoms to occur.

Etiology and Presentation

Midfoot arthritis has multiple etiologies, including inflammatory disorders, gout,¹² and neuropathic degeneration. Midfoot arthritis also can result from primary degradation of the cartilage itself, as in degenerative joint disease or osteoarthritis. Post-traumatic change resulting from fracture or dislocation of the midfoot bones is likely the leading cause of midfoot degeneration.

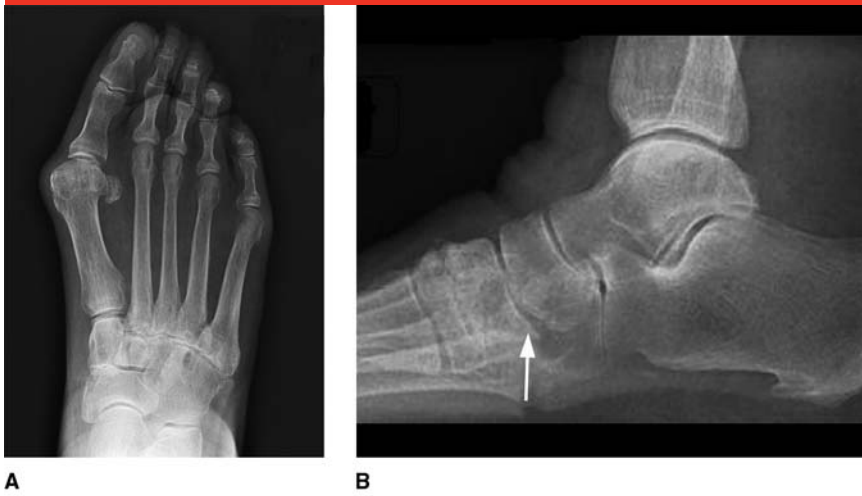The most common area of midfoot injury is the Lisfranc joint complex. The outcomes of these injuries correlate with the degree of anatomic incongruity of the Lisfranc joints.^{13,14} Injuries to the navicular and cuboid can also lead to significant arthrosis of the TMT joints through altered joint kinematics and altered loading. In a retrospective review of 155 patients with midfoot injuries, functional outcomes as measured by the AOFAS clinical rating scale were significantly worse in patients with combined Chopart and midfoot injuries than in those with either injury alone.¹ These combined injuries, which are often associated with high-energy motor vehicle accidents, are frequently missed when they are associated with additional trauma.¹⁵ Although fractures and fracture-dislocations of these bones can result

in severe functional impairment and arthrosis even with surgical reduction and stabilization, initial surgical intervention is recommended to realign the articulations and has been found to improve function in particular fracture patterns in small series.⁵ Midfoot arthritis may also result from the structural abnormalities from advanced adult-acquired flat-foot. These changes are characterized by loss of the longitudinal arch, valgus of the calcaneus, and forefoot abduction.^{16,17}

Physical Examination and Imaging

Patients with midfoot arthritis often present with pain with loading in the area of the midtarsal joints. Palpation is begun medially at the first TMT joint, which is best identified by the slight dorsal prominence or bossing at this articulation. The second TMT joint is recessed more proximally and thus, palpation is moved proximally 1 to 2 cm. These two joints tend to be the most tender in persons with midfoot arthritis. The third TMT joint is in line transversely with the first. Stabilizing the second through fifth rays and translating the first ray dorsal and plantar often exacerbates the pain. Range of motion (ROM) in these joints is minimal (4° to 7°) and often is not clinically important to quantify. Instability with excessive motion often presents with excessive pronation or midfoot collapse. Symptoms may be aggravated not only during level walking but with activities that require heel rise, such as stair ascent. Such activities require a functioning midfoot to effectively transmit the load of body weight to the forefoot. Loss of midfoot stability may also correspond to a loss of the longitudinal arch. In one series, 78% of patients with midfoot arthritis pre-

Figure 2



AP (A) and lateral (B) weight-bearing radiographs of a patient with primary midfoot arthritis involving all three columns. Note the sagging through the naviculocuneiform joint (arrow).

sented with abnormal foot posture or with difficulty in shoe wear.¹⁸ If present, the palpable bony prominences (ie, bossing) on the dorsum of the affected foot can result in irritation caused by shoe wear. The presence of gastrocnemius and/or soleus contracture should also be noted.

Weight-bearing AP, lateral, and internal rotation oblique radiographic views of the foot are helpful in the diagnosis and can characterize the location and extent of arthrosis. Radiographs of persons with primary degenerative arthritis may demonstrate a more pronated foot position than is seen with traumatic midfoot arthritis.¹⁹ This position manifests as a lower medial cuneiform height and a negative talo-first metatarsal angle.^{19,20} Lateral weight-bearing radiographs may also demonstrate sagging of the medial column, either at the naviculocuneiform or talonavicular joint (Figure 2). Further evaluation can be obtained with CT; however, currently weight bearing is not routinely simulated with CT.

Management

Nonsurgical

Lack of midfoot stability and altered midfoot loading may bring on symptoms of midfoot arthritis.²¹ Strategies implemented to relieve symptoms center on the improvement of midfoot stability and modification of load on the arthritic joints.

Nonsteroidal anti-inflammatory drugs (NSAIDs) are the standard first-line treatment of arthritic joint pain. Extended use of this class of drugs can be undesirable because of their adverse effects on the gastrointestinal system, concerns about the cardiovascular safety of certain selective NSAIDs, and cost.²² Scientific evidence of the effectiveness of adjuvant treatments (eg, selective injection of hyaluronic acid or cortisone) on midfoot arthritis pain is lacking.²³

Shoe modifications and orthoses have a large role in the nonsurgical management of midfoot arthritis.

Figure 3



Photograph of a rocker-bottom shoe into which a steel shank has been placed to aid in transferring weight during gait in a patient with midfoot arthritis.

The goal is to relieve symptoms by modifying the load borne by the midfoot. Stiff-soled shoes and rocker-bottom shoes have been used in an attempt to facilitate the transfer of weight during gait (Figure 3). Stiff carbon fiber full-length inserts can also be used to simulate a stiff-soled shoe. These inserts can be transferred between multiple pairs of shoes. Recent reports suggest that these inserts reduce the average plantar pressure and the contact time experienced by the medial midfoot.^{23,24} Kinematic data suggest that patients with midfoot arthritis demonstrate a so-called stiffening strategy during walking, which is reflected as reduced ROM of the first metatarsal during walking. However, during more challenging activities (eg, stair descent), a disproportionate increase in first metatarsal and calcaneal ever-

sion ROM has been demonstrated compared with matched control subjects, which suggests loss of midfoot stability.²⁵ By restricting first metatarsal ROM during walking, the full-length carbon insert may help in alleviating symptoms. Greater restriction of foot and ankle ROM through aggressive bracing may also provide relief of symptoms. The polypropylene ankle-foot clamshell orthosis can off-load the plantar foot by as much as 30%.²⁶ These orthotic devices often require the concurrent use of a rocker-bottom sole to aid in forward propulsion and are often viewed by patients as cumbersome.²³

Surgical

Surgical intervention may be indicated in patients with symptoms that have failed to respond to all nonsurgical therapy and in patients who believe that the severity of their symptoms necessitates additional treatment. Persons with traumatic midfoot arthritis tend to present in the fourth decade of life, and those with atraumatic degeneration of the midfoot typically present in the sixth decade.^{19,21}

Arthrodesis of the medial and middle columns is the mainstay of surgical treatment in persons with arthritis of the TMT and naviculocuneiform joints. Preoperative identification of the symptomatic joints is preferred. Clinical examination consists of joint palpation and confirmatory radiographic evaluation. Selective anesthetic injection of specific midfoot joints has been suggested, but recent cadaver studies have found that anesthetic leaks into adjacent joints in up to 20% of cases, thereby decreasing the selectivity of this tool.^{23,24} The decision regarding which articulations to fuse should also take into consideration the intraoperative assessment of the condition and the stability of these joints.

Medial and Middle Column Arthritis

Achievement of stability in the medial and middle columns requires that the first, second, and, potentially, third, TMT joints are included in the arthrodesis along with the corresponding intercuneiform joints. If there is sagging at the naviculocuneiform articulations, extension of the fusion to include that joint would be needed to avoid shifting load to these potentially compromised joints.

The surgical technique requires restoration of the mechanical alignment of the foot, adequate preparation of the bony surfaces, and rigid stabilization with lag screws and/or plates. In midfoot arthrodesis, longitudinal incisions are placed between the first and second metatarsals, and one incision is placed overlying the fourth metatarsal. An adequate skin bridge between the incisions must be maintained. A variety of plate and compression screw constructs has been suggested for midfoot arthrodesis, but there is no evidence indicating which offers the best clinical outcome resulting in successful fusion. Limited evidence suggests that plate fixation may provide increased mechanical stability compared with lag screw fixation alone.^{27,28} Bone graft augmentation for midfoot fusions has not been widely studied,²⁹ and there are no published studies regarding the effectiveness of biologic agents to augment fusion potential (Figures 4 and 5).

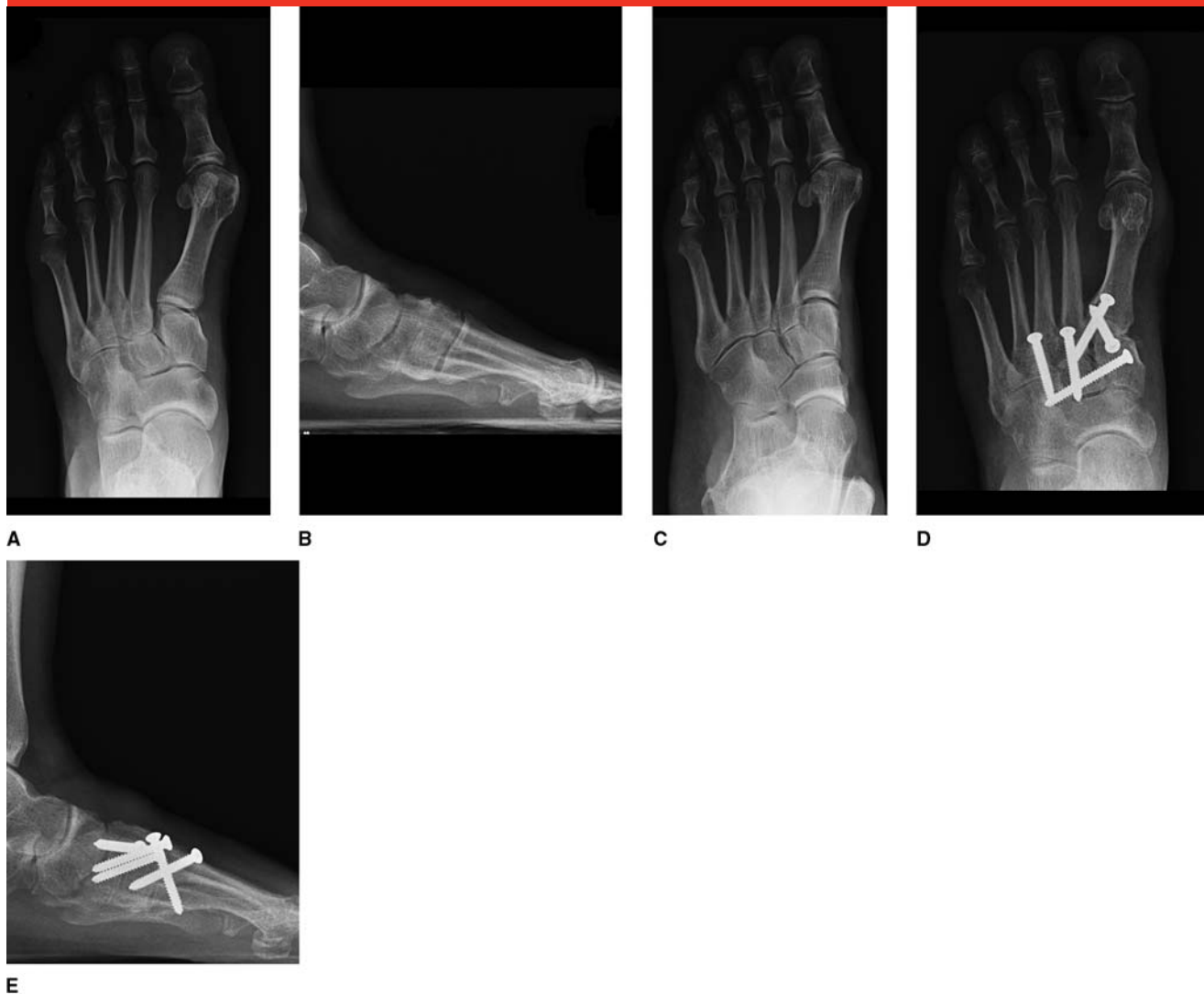Surgical complications in the medial and middle columns are varied in their presentation. Nonunion occurs in 3% to 7% of patients, with the elderly at highest risk.^{19,21,30} Postoperative neuroma may occur in up to 7% of patients¹⁹ and symptomatic hardware in 9%.²¹ Long-term complications include metatarsal stress fractures, metatarsalgia, and adjacent joint arthritis. Sesamoid pain after TMT fusion is also a common

complaint; it may be the result of the loss of first ray flexibility.²¹

Outcome studies have demonstrated that patients treated with arthrodesis for atraumatic midfoot arthritis report Medical Outcomes Study 36-Item Short Form postoperative scores comparable to those of a population group with generalized arthritis.¹⁴ These scores were lower than those of an age-matched control group. The American Orthopaedic Foot and Ankle Society (AOFAS) score is an unvalidated scale. However, significant improvements in pain (decreased by 60.5%), gait abnormality (59.7%), and alignment (47.1%) following arthrodesis have been noted based on the AOFAS score.^{14,20,30} Significant improvement in terms of pain, disability, and activity limitations have been shown with other outcomes measures, as well, following surgical fusion.¹⁹

The quality of the anatomic reduction has been identified as the most important predictor of a good outcome in persons with posttraumatic midfoot arthritis.^{31,32} Mann et al¹⁸ noted that 93% of patients who presented with traumatically induced midfoot arthritis reported satisfactory results following selective arthrodesis. Sangeorzan et al³¹ reported good to excellent results in 69% of patients with fracture or fracture-dislocation of the Lisfranc joint who had failed initial treatment and who underwent salvage arthrodesis. Myerson et al¹³ reported that the quality of the acute initial reduction of fractures or dislocation of the midfoot complex determined the long-term result in their series of 52 patients (55 Lisfranc injuries). Although surgical intervention is accompanied by decreased pain, the overall improvements in function may be modest.^{1,5,14,30,31} Age¹⁸ and mechanism of injury²⁰ have not been found to be significant predictors of outcomes after arthrodesis.

Figure 4



AP (A), lateral (B), and oblique (C) preoperative weight-bearing radiographs of a 45-year-old woman who developed midfoot arthritis following a crush injury. AP (D) and lateral (E) weight-bearing radiographs obtained 5 months after fusion of the first through third TMT joints and fusion of the intercuneiform joints with Synthes 3.5-mm solid shank lag screw fixation (West Chester, PA).

Lateral Column Midfoot Arthritis

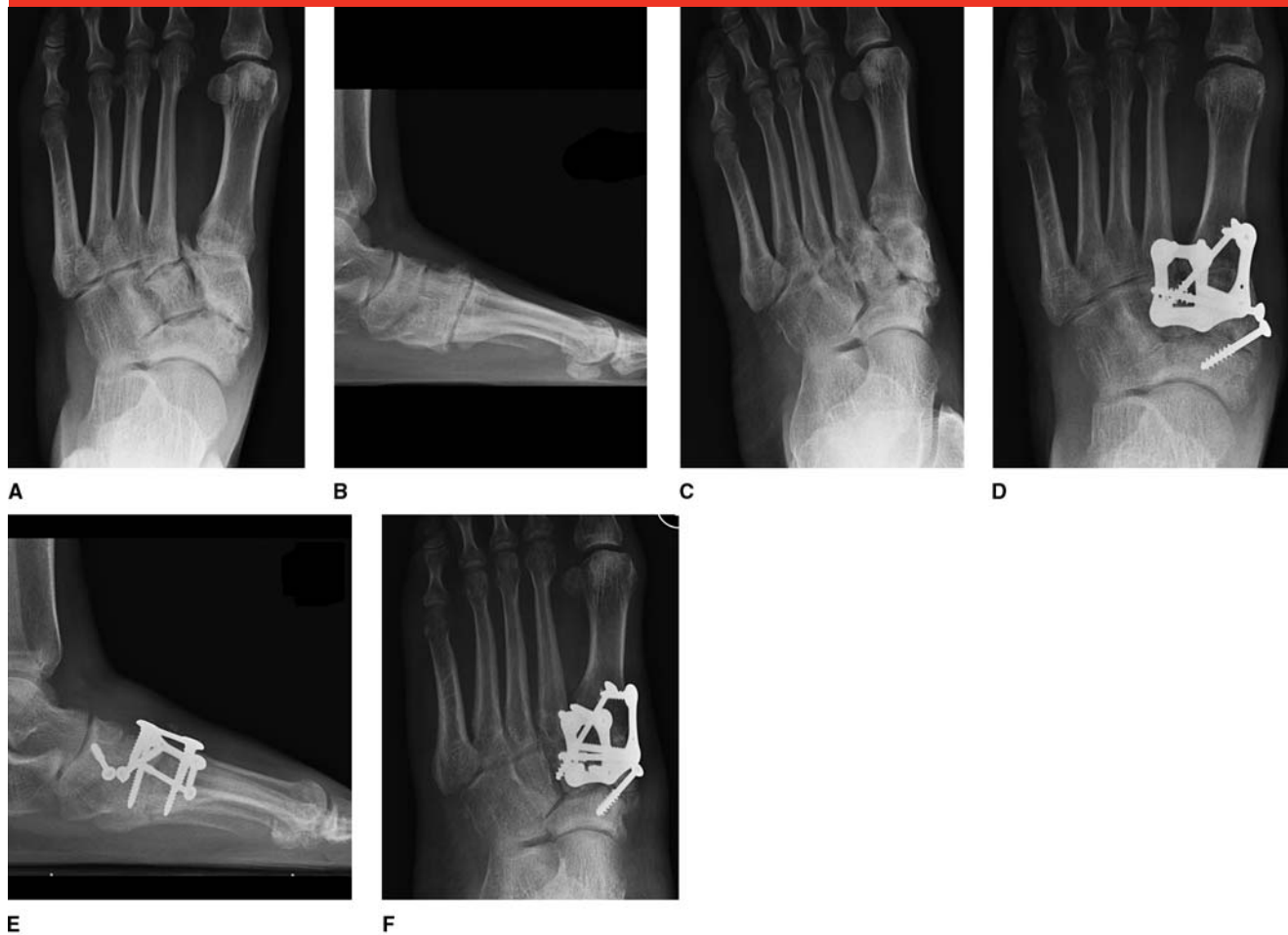Treatment of arthritis of the lateral TMT joints continues to evolve. Few published studies suggest performing arthrodesis of the more mobile lateral column. In fact, several suggest that bony fusion of these rays may lead to other complications. There is concern that fusion of the cuboid articulations with the base of the fourth and fifth metatarsals may lead to chronic lateral foot pain and an

increased rate of nonunion; additionally, such fusion may predispose patients to developing stress fractures.²⁰ Raikin and Schon³³ determined that arthrodesis of the fourth and fifth metatarsal joints can produce good outcomes in patients with lateral midfoot collapse, with rocker-bottom deformity, and with severe arthritic degeneration that is recalcitrant to conservative nonsurgical management. Complications follow-

ing lateral column fusion include stress fractures of the lateral metatarsals, prominent or broken hardware, and subjective lateral foot stiffness.

There is no strict contraindication to lateral column arthrodesis. However, several authors agree that motion-preserving procedures may be beneficial.³⁴ Alternative procedures have been developed to maintain motion of the fourth and fifth TMT joints while providing symp-

Figure 5



AP (A), lateral (B), and oblique (C) preoperative weight-bearing radiographs of a 35-year-old woman who presented with severe midfoot pain of the first and second TMT joints and the medial naviculocuneiform joint (medial column). She sustained life-threatening injuries in a motor vehicle accident at age 22 years. Lisfranc fracture was recognized at that time, but it was managed nonsurgically because of the presence of other medical issues. AP (D), lateral (E), and oblique (F) weight-bearing radiographs obtained 5 months after medial column arthrodesis with an Integra midfoot plate construct (Plainsboro, NJ). The third arm of the plate was cut off because the third TMT joint did not require arthrodesis. One solid shank 3.5-mm Synthes screw was placed in lag fashion for the medial naviculocuneiform articulation.

tom relief. Berlet et al³⁵ retrospectively examined the results of lateral TMT joint resection with peroneus tertius soft-tissue interposition. Most patients in this series had traumatic lateral complex arthritis that was refractory to nonsurgical management. In the treating surgical procedure, the joints were resected, and the soft tissue was placed in the void and secured with a Kirschner wire (Figure 6). The wire was removed before the patients initiated weight bearing at 6

weeks postoperatively. Of the eight patients who underwent the surgery, six were satisfied, with an average decrease in preoperative pain of 35%. The authors subjectively estimated that lateral column motion was preserved.

Another proposed motion-preserving alternative is ceramic interpositional arthroplasty. Shawen et al³⁴ placed spherical devices into the lateral TMT articulation after joint débridement. The bases of the fourth and fifth metatar-

sals were approached dorsally, with subsequent débridement of the joints. Matching spherical depressions were created in the joint surfaces, and a size-matched implant was inserted. Patients were transitioned to weight-bearing activities at 6 weeks postoperatively. At an average follow-up of 34 months, the 13 patients had an 87% improvement in AOFAS score, and their visual analog pain rating improved 42%. Regardless of the technique used for management of the lateral column, appropriate

Figure 6

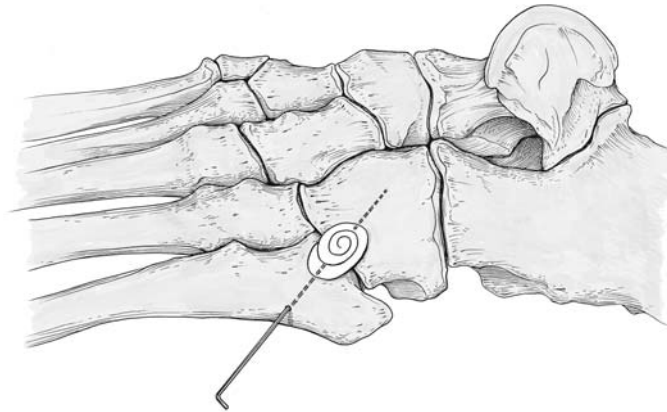
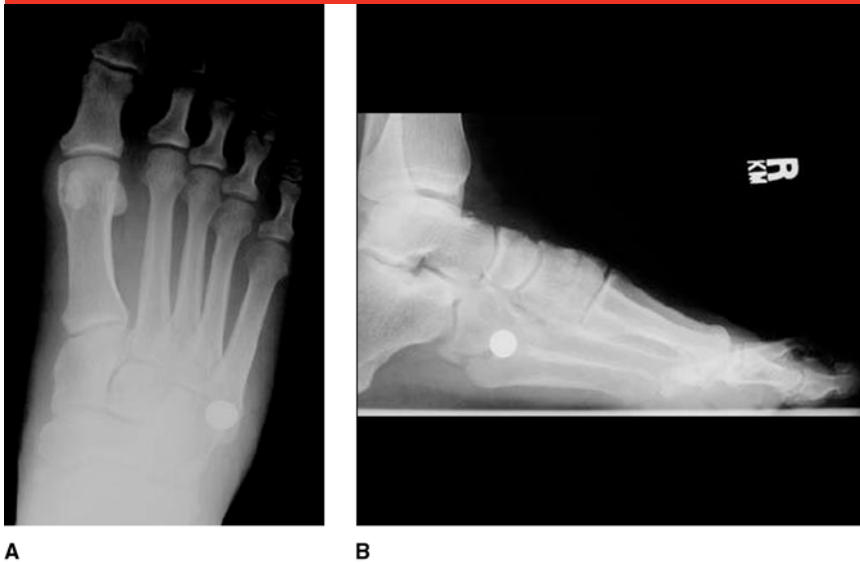


Illustration demonstrating soft-tissue interpositional arthroplasty to manage lateral column midfoot arthritis. The soft tissue is secured with a Kirschner wire. (Redrawn with permission from Berlet GC, Hodges Davis W, Anderson RB: Tendon arthroplasty for basal fourth and fifth metatarsal arthritis. *Foot Ankle Int* 2002;23[5]:440-446.)

Figure 7



AP (A) and lateral (B) radiographs following fifth tarsometatarsal joint ceramic arthroplasty to manage midfoot arthritis. (Reproduced with permission from Shawen SB, Anderson RB, Cohen BE, Hammit MD, Davis WH: Spherical ceramic interpositional arthroplasty for basal fourth and fifth metatarsal arthritis. *Foot Ankle Int* 2007;28[8]:896-901.)

attention to final position of the column and good surgical technique are paramount to achieving favorable outcomes (Figure 7).

Senior Author’s Preferred Technique

The senior author (JFB) considers surgical management only after the

patient has failed all nonsurgical options and has been informed that the outcomes are approximately 60% relief of pain. Gait may remain limited, and in 10% of patients, complication rates necessitate a second surgery. The patient is asked to identify the location of the pain, the affected area is palpated, and weight-bearing radiographs are obtained. If there is sagging of the medial column at the naviculocuneiform articulation, the medial naviculocuneiform joint is included in the arthrodesis. Particular attention is given to the range of motion of the ankle. Heel cord lengthening is performed in the patient with limited dorsiflexion motion or a positive Silfverskiöld test. Most commonly the first and second TMT joints require fusion to the corresponding intervening intercuneiform joints. The third TMT joint is rarely involved. Even more rarely are the fourth and fifth TMT joints symptomatic.

A popliteal block is used in conjunction with a spinal or general anesthetic for postoperative pain control. A calf or thigh tourniquet can be used. An incision is made between the first and second TMT joints. A “lazy” C with the concavity medial can be useful for access. Care must be taken to avoid the neurovascular bundle, which lies over the base of the second metatarsal. The dissection is performed with scissors, but full-thickness flaps are raised once the dissection is down to bone. The first and second TMT joints are exposed, and a small untoothed laminar spreader can aid in exposing the joints for removal of the cartilage with small curets. The first TMT joint is prepared with the curet, after which it is drilled with a Kirschner wire to infract the subchondral bone to facilitate fusion. The second TMT and the intercuneiform joints are prepared in a similar fashion. Care is taken in the 1,2 interspace where the

first perforator from the dorsalis pedis artery dives down to make up the plantar arch. Injury to this structure can cause profuse bleeding. If necessary, the third TMT joint can be approached through a second incision made longitudinally on the lateral edge of the fourth metatarsal base. The medial naviculocuneiform articulation is approached through extension of the proximal aspect of the medial incision. However, to avoid rotational malalignment, this dissection is done only after the first and second TMT joints have been stabilized. Small reduction clamps and pelvic reduction clamps are helpful with preliminary reduction of the TMT joints.

Stiff, thin plates are placed along the dorsal aspect of the repair. A box can be made using the Synthes Modular Foot System 2.7-mm condylar modular foot plate stabilization construct (West Chester, PA), with two screws placed in each bone. The third limb of the Integra dorsal Lisfranc plate (Integra LifeSciences, Plainsboro, NJ) can be cut off for use in patients who do not require arthrodesis of the third TMT joint. Plates that can be bent with the surgeon's bare hands are not strong enough and tend to break, leading to loss of alignment and stability.

AP, lateral, and oblique views of the foot are obtained intraoperatively using mini-fluoroscopy to aid in the reduction and confirm hardware placement. Demineralized bone matrix is placed into the areas of the fusion to fill any defects in bone-to-bone contact. The skin is closed with 3-0 nylon suture. If a nerve block was not administered preoperatively, an ankle block is performed with 0.25% bupivacaine hydrochloride for postoperative pain control. A bulky dressing and posterior splint are applied.

The patient is instructed to adhere to "toes above the nose," non-

weight-bearing and to return 1 week postoperatively for a dressing change and cast application. The dressing and cast are changed again at 3 weeks, and the sutures are removed. The patient must remain non-weight-bearing for 3 months. Radiographs of the foot are obtained at 6 and 12 weeks. The patient is placed in a low-tide walking boot at 12 weeks, and physical therapy is begun for ankle and toe rehabilitation. The transition from the boot to a shoe occurs based on the patient's tolerance. Final outcome of the fusion is not known until 1 year after surgery.

Summary

Midfoot arthritis is typically post-traumatic in nature and can cause significant functional limitations. Nonsurgical options are limited to NSAIDs, full-length rigid foot plates, and shoe modifications. Surgical intervention can provide relief of symptoms, with outcomes correlating with the degree of anatomic reduction obtained. There is consensus that arthrodesis of the medial and middle joints improves stability and decreases pain, but does not eliminate pain or normalize function.

References

Evidence-based Medicine: Levels of evidence are described in the table of contents. In this article, reference 30 is a level I study. References 1 and 14 are level III studies. References 2, 4-6, 13, 18-20, 29, 32, 34, and 35 are level IV studies. References 15, 22, and 30 are level V expert opinion. Citation numbers printed in **bold type** indicate references published within the past 5 years.

1. Richter M, Wippermann B, Krettek C, Schrott HE, Hufner T, Therman H: Fractures and fracture dislocations of the midfoot: Occurrence, causes and long-

term results. *Foot Ankle Int* 2001;22(5):392-398.

2. Hardcastle PH, Reschauer R, Kutscha-Lissberg E, Schoffmann W: Injuries to the tarsometatarsal joint: Incidence, classification and treatment. *J Bone Joint Surg Br* 1982;64(3):349-356.
3. Chong M, Sochor M, Ipaktchi K, Brede C, Poster C, Wang S: The interaction of 'occupant factors' on the lower extremity fractures in frontal collision of motor vehicle crashes based on a level I trauma center. *J Trauma* 2007;62(3):720-729.
4. Goossens M, De Stoop N: Lisfranc's fracture-dislocations: Etiology, radiology, and results of treatment. A review of 20 cases. *Clin Orthop Relat Res* 1983;176:154-162.
5. Arntz CT, Hansen ST Jr : Dislocations and fracture dislocations of the tarsometatarsal joints. *Orthop Clin North Am* 1987;18(1):105-114.
6. Peicha G, Labovitz J, Seibert FJ, et al: The anatomy of the joint as a risk factor for Lisfranc dislocation and fracture-dislocation: An anatomical and radiological case control study. *J Bone Joint Surg Br* 2002;84(7):981-985.
7. Sayeed SA, Khan FA, Turner NS III, Kitaoka HB: Midfoot arthritis. *Am J Orthop* 2008;37(5):251-256.
8. Desmond EA, Chou LB: Current concepts review: Lisfranc injuries. *Foot Ankle Int* 2006;27(8):653-660.
9. Sarrafian S: Syndesmology, in *Anatomy of the Foot and Ankle: Descriptive, Topographic, Functional*. Philadelphia, PA, Lippincott Company, 1993, pp 159-217.
10. Ouzounian TJ, Shereff MJ: In vitro determination of midfoot motion. *Foot Ankle* 1989;10(3):140-146.
11. Gazdag AR, Cracchiolo A III : Rupture of the posterior tibial tendon: Evaluation of injury of the spring ligament and clinical assessment of tendon transfer and ligament repair. *J Bone Joint Surg Am* 1997;79(5):675-681.
12. Sack K: Monarthrosis: Differential diagnosis. *Am J Med* 1997;27;102(1A):30S-34S. Medline
13. Myerson MS, Fisher RT, Burgess AR, Kenzora JE: Fracture dislocations of the tarsometatarsal joints: End results correlated with pathology and treatment. *Foot Ankle* 1986;6(5):225-242.
14. Kuo RS, Tejjwani NC, Digiovanni CW, et al: Outcome after open reduction and internal fixation of Lisfranc joint injuries. *J Bone Joint Surg Am* 2000;82-A(11):1609-1618.
15. Graziano TA, Snider DW, Steinberg RI: Crush and avulsion injuries of the foot:

- Their evaluation and management. *J Foot Surg* 1984;23(6):445-450.
16. Greisberg J, Hansen ST Jr, Sangeorzan B: Deformity and degeneration in the hindfoot and midfoot joints of the adult acquired flatfoot. *Foot Ankle Int* 2003; 24(7):530-534.
 17. Hintermann B, Valderrabano V, Kundert HP: Lengthening of the lateral column and reconstruction of the medial soft tissue for treatment of acquired flatfoot deformity associated with insufficiency of the posterior tibial tendon. *Foot Ankle Int* 1999;20(10):622-629.
 18. Mann RA, Prieskorn D, Sobel M: Mid-tarsal and tarsometatarsal arthrodesis for primary degenerative osteoarthritis or osteoarthritis after trauma. *J Bone Joint Surg Am* 1996;78(9):1376-1385.
 19. Jung HG, Myerson MS, Schon LC: Spectrum of operative treatments and clinical outcomes for atraumatic osteoarthritis of the tarsometatarsal joints. *Foot Ankle Int* 2007;28(4):482-489.
 20. Komenda GA, Myerson MS, Biddinger KR: Results of arthrodesis of the tarsometatarsal joints after traumatic injury. *J Bone Joint Surg Am* 1996; 78(11):1665-1676.
 21. Rao SN, Baumhauer J: Midfoot arthritis: Nonoperative options and decision making for fusion. *Tech Foot Ankle Surg* 2008;7:188-195.
 22. Mukherjee D, Nissen SE, Topol EJ: Risk of cardiovascular events associated with selective COX-2 inhibitors. *JAMA* 2001; 286(8):954-959.
 23. Rao S, Baumhauer JF, Becica L, Nawoczenski DA: Shoe inserts alter plantar loading and function in patients with midfoot arthritis. *J Orthop Sports Phys Ther* 2009;39(7):522-531.
 24. Khosla ST, Thiele R, Baumhauer JF: Ultrasound guidance for intra-articular injections of the foot and ankle. *Foot Ankle Int* 2009;30(9):886-890. Medline.
 25. Rao S, Baumhauer JF, Tome J, Nawoczenski DA: Comparison of in vivo segmental foot motion during walking and step descent in patients with midfoot arthritis and matched asymptomatic control subjects. *J Biomech* 2009;42(8): 1054-1060.
 26. Saltzman CL, Johnson KA, Goldstein RH, Donnelly RE: The patellar tendon-bearing brace as treatment for neurotrophic arthropathy: A dynamic force monitoring study. *Foot Ankle* 1992;13(1):14-21.
 27. Suh JS, Amendola A, Lee KB, Wasserman L, Saltzman CL: Dorsal modified calcaneal plate for extensive midfoot arthrodesis. *Foot Ankle Int* 2005;26(7):503-509.
 28. Marks RM, Parks BG, Schon LC: Midfoot fusion technique for neuroarthropathic feet: Biomechanical analysis and rationale. *Foot Ankle Int* 1998;19(8):507-510.
 29. Bibbo C, Anderson RB, Davis WH: Complications of midfoot and hindfoot arthrodesis. *Clin Orthop Relat Res* 2001;391:45-58.
 30. Ly TV, Coetzee JC: Treatment of primarily ligamentous Lisfranc joint injuries: Primary arthrodesis compared with open reduction and internal fixation. A prospective, randomized study. *J Bone Joint Surg Am* 2006;88(3): 514-520.
 31. Sangeorzan BJ, Veith RG, Hansen ST Jr: Salvage of Lisfranc's tarsometatarsal joint by arthrodesis. *Foot Ankle* 1990; 10(4):193-200.
 32. Arntz CT, Veith RG, Hansen ST Jr: Fractures and fracture-dislocations of the tarsometatarsal joint. *J Bone Joint Surg Am* 1988;70(2):173-181.
 33. Raikin SM, Schon LC: Arthrodesis of the fourth and fifth tarsometatarsal joints of the midfoot. *Foot Ankle Int* 2003;24(8): 584-590.
 34. Shawen SB, Anderson RB, Cohen BE, Hammit MD, Davis WH: Spherical ceramic interpositional arthroplasty for basal fourth and fifth metatarsal arthritis. *Foot Ankle Int* 2007;28(8):896-901.
 35. Berlet GC, Hodges Davis W, Anderson RB: Tendon arthroplasty for basal fourth and fifth metatarsal arthritis. *Foot Ankle Int* 2002;23(5):440-446.